

Protection from photodamage by topical application of caffeine after ultraviolet irradiation

S-W. Koo, S. Hirakawa,* S. Fujii, M. Kawasumi† and P. Nghiem†

Cutaneous Biology Research Center, Massachusetts General Hospital, Harvard Medical School, 149 13th St, Charlestown, MA 02129, U.S.A.

*Current address: Department of Dermatology, Ehime University School of Medicine, Toon, Ehime 791-0295, Japan

†Current address: Department of Medicine, Division of Dermatology, University of Washington, 815 Mercer St, Seattle, WA 98109, U.S.A.

Summary

Correspondence

P. Nghiem.

E-mail: pnghiem@u.washington.edu

Accepted for publication

14 November 2006

Key words

apoptosis, caffeine, hairless mouse, photodamage, photoprotection, ultraviolet

Conflicts of interest

None declared.

Background Characterization of mechanisms that can reverse residual damage from prior skin exposure to ultraviolet (UV) would be of considerable biological and therapeutic interest. Topical caffeine application to mouse skin that had previously been treated with UV has been shown to inhibit the subsequent development of squamous cell carcinomas.

Objectives We used an established mouse photodamage model to investigate other possible effects of topical caffeine application after UV.

Methods SKH-1 hairless mice were treated with ultraviolet B (UVB) followed immediately by topical application of caffeine or vehicle three times weekly for 11 weeks.

Results Caffeine applied topically after UV treatment resulted in a significant decrease in UV-induced skin roughness/transverse rhytides as assessed by treatment-blinded examiners. Histologically, topical caffeine application after a single dose of UVB more than doubled the number of apoptotic keratinocytes as evaluated by sunburn cell formation, caspase 3 cleavage and terminal deoxynucleotidyl transferase-mediated dUTP-biotin nick-end labelling (TUNEL) staining. A trend towards decreased solar elastosis was noted in the caffeine-treated group although this was not statistically significant. Other histological parameters including epidermal hyperplasia, solar elastosis and angiogenesis were increased in mice treated with UV but topical application of caffeine did not alter these particular UV effects.

Conclusions These findings support the concept that topical application of caffeine to mouse skin after UV irradiation promotes the deletion of DNA-damaged keratinocytes and may partially diminish photodamage as well as photocarcinogenesis.

Prolonged sun exposure of human skin during youth leads later in life to photodamage including wrinkle formation, solar elastosis and degradation of matrix macromolecules.¹⁻⁵ Prior sun exposure also leads to an increased risk for the development of epithelial skin cancers in part via direct mutation of DNA.^{6,7} Effective approaches to diminish residual ultraviolet (UV) damage in skin may decrease photoageing and subsequent skin cancer development.

The chronically UV-exposed hairless mouse has provided an important animal model to study the causal association of chronic UV exposure with epidermal and dermal pathophysiology.^{8,9} Histological changes of photoageing include damage to collagen fibres, excessive deposition of abnormal elastic fibres, increase of glycosaminoglycans and matrix metalloproteinases (MMP).¹⁰⁻¹⁵

Epidermal changes have also been associated with chronic low-dose UV irradiation. In mice, these include an increase in

the number of stratum corneum layers and an increase in the number of keratinocytes expressing filaggrin (a marker of terminal differentiation).¹⁶ In humans, chronic epidermal UV-induced changes include atypical/hyperproliferative keratinocytes and an increased risk of basal and squamous cell carcinoma.

Caffeine has been shown to prevent ultraviolet B (UVB)-induced skin cancer development in an 'at risk' mouse model.¹⁷ In this model hairless mice are treated twice weekly with UVB for 20 weeks at which time they have no skin tumours, but they will go on to develop them without any further UV treatment. After all UVB treatments were completed, mice were treated with either vehicle or topical caffeine. Treatment with topical caffeine significantly diminished nonmalignant and malignant tumours by 44% and 72%, respectively. One proposed mechanism of topical caffeine inhibition on tumorigenesis invokes increased apoptosis in the tumours.¹⁷ One possible mediator of

this effect is ATR (ataxia–telangiectasia and Rad-3-related). ATR belongs to a family of large protein kinases related in sequence to phosphatidylinositol kinase, which are involved in sensing various cellular stresses including UV DNA damage and halting replication so the cell has time to repair its DNA.^{18,19} Caffeine can ‘override’ the replication checkpoint function of ATR causing cells to undergo premature chromatin condensation and subsequent apoptosis.²⁰

The effects of topical caffeine on skin are also of interest as this agent is included in a number of skin care products marketed in combination with other agents as lipolytics.^{21–23} Little or no data has been published on the effects of topical application of caffeine itself on human skin although products including soaps are marketed with caffeine added.

In this study, we examined the role of caffeine in protection from UVB-induced chronic photodamage and in apoptosis of keratinocytes shortly after UVB exposure. We found that topical application of caffeine after UVB diminished cumulative photodamage as assessed visually by treatment-blinded observers and was associated with histological changes including a marked increase in the fraction of DNA-damaged keratinocytes deleted after UVB.

Materials and methods

Animals

This study was approved by the animal care and use committee of the Massachusetts General Hospital. Female SKH-1 hairless mice were purchased from Charles River Laboratories (Wilmington, MA, U.S.A.). The animals were 12–16 weeks old at the beginning of the experiment. Mice were given water and Purina Laboratory Chow 5001 diet from Ralston-Purina (St Louis, MO, U.S.A.) *ad libitum*, and they were kept on a 12-h light/12-h dark cycle.

Materials

Caffeine (Sigma, St Louis, MO, U.S.A.) was dissolved in acetone at 1.2% (wt/vol) by 5 min of warming to 50 °C. Monoclonal rat antimouse CD31 antibody was purchased from PharMingen (San Diego, CA, U.S.A.) and antirat IgG conjugated with AlexaFluor 594 was obtained from Molecular Probes (Eugene, OR, U.S.A.).

Ultraviolet radiation source

The UV lamps used (Southern New England Ultraviolet, Branford, CT, U.S.A.) emitted UVB (280–320 nm; 75–80% of total energy) and UVA (320–375 nm; 20–25% of total energy). There was little or no radiation below 280 nm or above 375 nm. The height of the lamps was adjusted to deliver 0.35 mW cm⁻² at the dorsal skin surface. The dose of UVB was quantified with a model IL-1700 research radiometer/photometer (International Light, Newburyport, MA, U.S.A.) fitted with a UVB sensor.

Chronic ultraviolet treatment

A group of 21 animals were divided into control (vehicle; six animals) and three treatment (five each) groups. The four experimental groups were treated as follows: group 1 = vehicle (acetone); group 2 = caffeine; group 3 = UV + vehicle (acetone); group 4 = UV + caffeine. UVB was used at a starting dose of 45 mJ cm⁻² and was increased according to a UV protocol as shown in Figure 1a and based on Kligman *et al.*⁸ Immediately after UV irradiation 100 µL of either 1.2% caffeine in acetone or acetone only were applied. The frequency of treatment was set at three times per week (33 total treatments during 11 weeks). Skin specimens from the central dorsum of the mice were obtained 48 h after the last treatment. Care was taken to harvest the same area of back skin from each mouse. The skin samples were fixed in 10% buffered formalin or frozen in OCT compound (Sakura Finetek USA, Torrance, CA, U.S.A.).

Acute ultraviolet/apoptosis assay

To assess the effect of topical caffeine on apoptosis following a single dose of UV, a group of 20 hairless mice were divided into four experimental groups: vehicle (control); caffeine; UV + vehicle (acetone); UV + caffeine. Immediately after a single dose of UVB (45 mJ cm⁻²) 100 µL of either 1.2% caffeine in acetone or acetone alone were applied. Six hours after the treatment, the mice were sacrificed and the back skin of each mouse was harvested for haematoxylin and eosin, terminal deoxynucleotidyl transferase-mediated dUTP-biotin nick-end labelling (TUNEL) and staining for caspase 3 cleavage. After routine haematoxylin and eosin stains were performed on 5-µm paraffin-embedded skin sections, apoptotic sunburn keratinocytes were counted at 200 × magnification. Sunburn cells were identified in the epidermis as cells with a homogeneous densely staining glassy eosinophilic cytoplasm and a small hyperchromatic condensed pyknotic nucleus that can readily be seen with routine histological sections of the skin using light microscopy.²⁴ These examinations were performed blindly with respect to treatment group. Besides sunburn cell morphological identification, apoptotic cells were also identified by TUNEL staining using the Fluorescein-FragEL DNA fragmentation kit (Oncogene, Cambridge, MA, U.S.A.) according to the manufacturer's instructions. Apoptosis was further correlated by immunohistochemical staining of paraffin-embedded sections using a polyclonal rabbit antimouse cleaved caspase 3 antibody (Cell Signaling, Danvers, MA, U.S.A.).

Visual photodamage grading

Forty-eight hours after the final treatment in the chronic assay, each hairless mouse was anaesthetized, and visual grading of transverse rhytides/skin roughness of each animal was carried out independently by four observers who were blinded as to the treatment. Grading scores for photodamage

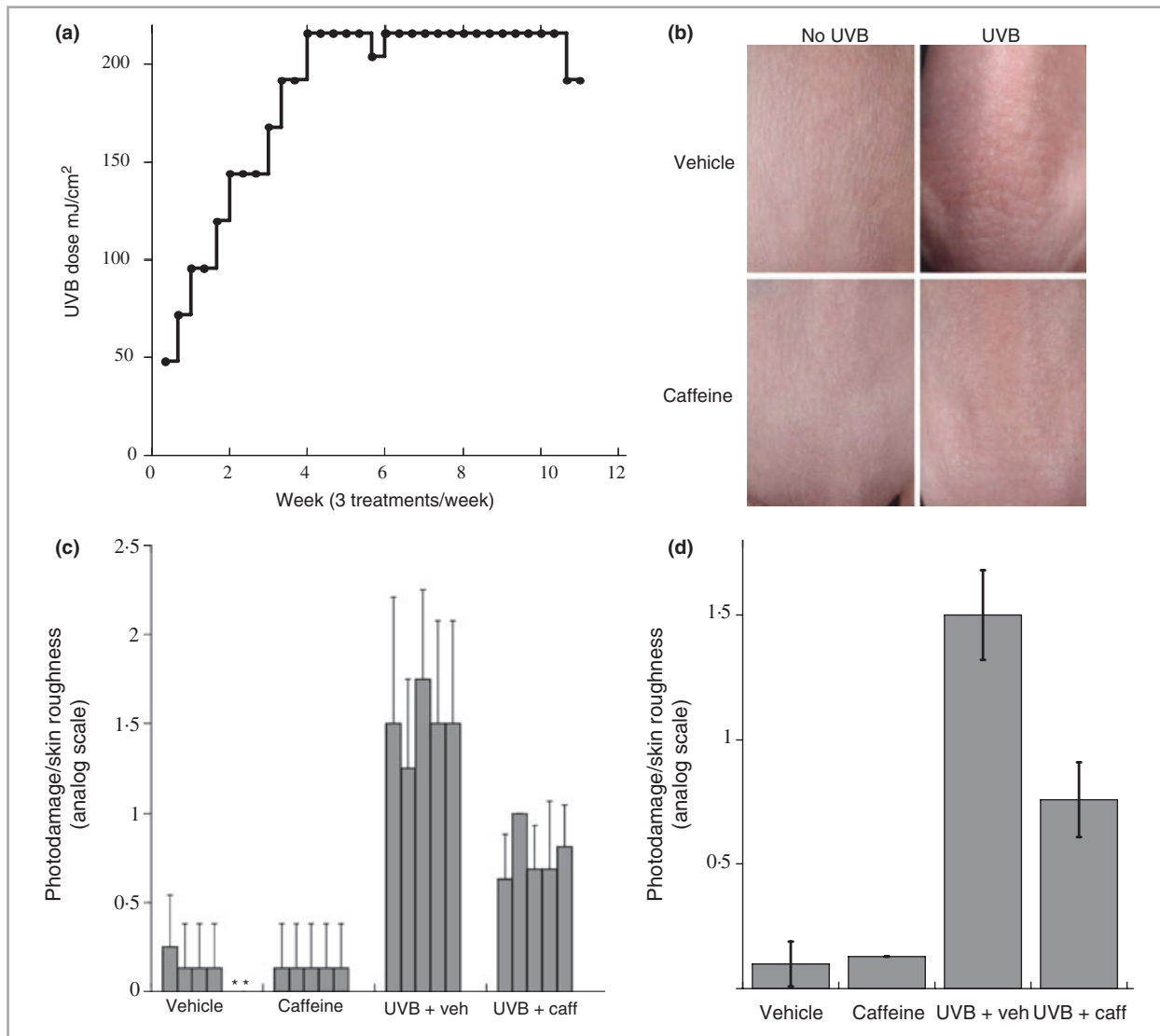


Fig 1. (a) Experimental design for topical application of caffeine after ultraviolet (UV) treatment in a chronic photodamage assay. Each dot ‘.’ represents one UV treatment, followed immediately by application of topical 1.2% caffeine or vehicle (acetone). Forty-eight hours after the final UV treatment mice were examined and photographed, and tissues were harvested for analysis. (b) Photographs of mouse back skin 48 h after final UV treatment in an 11-week course. One representative photo per treatment group is shown. (c) Visual photodamage/skin roughness graded 48 h after final treatment. The two asterisks (control) indicate mice that were graded as zero for photodamage by all four evaluators. Grading was carried out blindly as to the treatment received. Grading scores for damage severity were on a 0–3 scale. Each column represents the average grades assigned to a single mouse by the four observers. Six mice were included in the vehicle group and there were five mice in each of the other three groups. ‘caff’ = caffeine; ‘veh’ = vehicle. The presence of photodamage was significantly decreased in UVB/caffeine-treated mice ($n = 5$) compared with UVB/vehicle-treated mice ($P < 0.05$) with no effect of topical caffeine alone. (d) Average photodamage grading for each experimental group. Each column represents the average grades of all mice in that group as evaluated by four observers. Error bar represents standard error. $P = 0.0039$ for UV/vehicle relative to vehicle, $P = 0.0159$ for UV/caffeine relative to UV/vehicle. Nonparametric exact tests were used with an adjustment for multiple comparisons. $n =$ six mice in control and five mice in other groups.

severity were based on a 0–3 scale with 0 for normal skin and 3 for heavily photodamaged/rough skin. Observers could use 0.5 increments to record their grading of each mouse. Nonparametric exact tests were used with an adjustment for multiple comparisons by the Dana-Farber Skin Cancer SPORE Biostatistics Core Facility (Boston, MA, U.S.A.).

Histology

For haematoxylin and eosin staining, skin samples were fixed in 10% buffered formalin and embedded in paraffin. Then, 5- μ m sections were stained with haematoxylin and eosin. Representative photographs of stained skin sections ($n = 15$ in control and UV + vehicle and $n = 12$ in caffeine and

UV + caffeine groups) were taken in control and treatment groups and subsequently analysed in a treatment-blind manner.

CD31 staining

To analyse blood vessel formation in four experimental groups, immunofluorescence staining for endothelial cell marker CD31 was performed on 5- μ m frozen sections, using a monoclonal rat antimouse CD31 antibody (PharMingen). Anti-rat IgG conjugated with AlexaFluor 594 (Molecular Probes) was used as a secondary antibody. Representative photographs were obtained from each experimental group and blood vessels were counted within \approx 50- μ m distance from the dermal-epidermal junction. The number of blood vessels was compared between the four experimental groups.

Mouse epidermal thickness and solar elastosis

Representative photographs of haematoxylin and eosin-stained skin sections ($n = 15$ in control and UV + vehicle and $n = 12$ in caffeine and UV + caffeine groups) were used. Each picture was measured at three representative locations for epidermal thickness. Solar elastosis was defined as irregular pink thickened collagen just below the dermal-epidermal junction. For solar elastosis, the following grading scores were used: 0 = none, 1 = mild, 2 = moderate, 3 = severe. Each picture was evaluated by four observers blinded as to the treatment received. Sample photographs of each grade of solar elastosis were provided to the observers for comparison and consistency of grading.

Elastin content

Desmosine is a cross-link amino acid that is unique in the skin to elastin. The quantity of desmosine can be used as an indicator of elastin in a tissue. To evaluate whether caffeine treatment and UV-induced photodamage was related to changes in dermal elastin, desmosine quantitation was kindly carried out by Dr Barry Starcher (UT Health Center, Tyler, TX, U.S.A.).²⁵

Stratum corneum layers

To quantify the number of stratum corneum layers in skin samples, frozen 5- μ m sections were stained with a 1% aqueous solution of safranin (Sigma) and observed under a microscope within 30 min after application of 2% potassium hydroxide solution and a cover slip.

Results

Visible skin changes induced by ultraviolet B irradiation and topical applications of caffeine

Forty-eight hours after the final UV treatment in an 11-week course (Fig. 1a) photographs of mouse back skin were

obtained in order to evaluate the degree of UVB-induced skin changes (Fig. 1b). Skin roughness and transverse rhytides (wrinkles) were graded in anaesthetized mice by four treatment-blinded observers. Figure 1c shows the photodamage grade of each individual mouse with data averaged over the four observers as described in Materials and methods. Figure 1d shows the photodamage average grade of the observers for all mice in each group. Photodamage was significantly increased in UVB/vehicle-treated mice ($n = 5$) compared with nonirradiated control mice ($n = 6$, $P < 0.01$; Fig. 1c,d). The presence of photodamage was significantly decreased in UVB/caffeine-treated mice ($n = 5$) compared with UVB/vehicle-treated mice ($P < 0.05$) with no effect of topical caffeine alone (Fig. 1c,d).

Skin histological changes induced by ultraviolet B irradiation and topical applications of caffeine

Forty-eight hours after final UV and/or caffeine treatment mouse back skin was harvested for histological analysis following photography and visual grading. No significant histological abnormalities were found in mice treated with vehicle or caffeine alone (Fig. 2a). The morphology of abortive hair follicles and epidermal cysts that are characteristic of SKH-1 hairless mice was evaluated histologically and did not vary among experimental groups in terms of number or size. This suggests that alterations in these structures routinely found in hairless mouse skin do not explain the observed differences in photoageing among treatment groups (Fig. 2a). Epidermal hyperplasia was markedly increased and essentially identical between the UV/vehicle- and UV/caffeine-treated groups compared with nonirradiated controls (Fig. 2a,b).

Distinct histological changes of solar elastosis (see Materials and methods) were observed in the UV/vehicle- and UV/caffeine-treated mice relative to nonirradiated controls (Fig. 2c). There was a trend to less solar elastosis in UV/caffeine-treated mice than in UV/vehicle-treated mice compared but the difference was not statistically significant (Fig. 2c). The total amount of dermal elastin as assessed by desmosine quantitation did not show a significant change between the UV/vehicle and UV/caffeine groups. Values for the four treatment groups (expressed as pmol desmosine/ μ g skin \pm SEM) were: control = 101 ± 4 ; caffeine = 137 ± 9 ; UV/vehicle = 123 ± 8 ; and UV/caffeine = 130 ± 9 .

The number of stratum corneum layers was counted in each group under light microscopy after safranin/potassium hydroxide staining of frozen sections. Forty sections were counted for each treatment condition. Neither UV treatment (average 5.2 stratum corneum layers) nor caffeine treatment (5.6 layers) significantly affected the number of stratum corneum layers in mouse skin (control 5.2 layers). An increase to 6.8 layers in the UV/caffeine-treated mouse group, while statistically significant, was not viewed as likely to explain the observed photodamage differences.

To investigate the effects of caffeine on UVB-induced angiogenesis, we performed CD31 immunofluorescence staining on

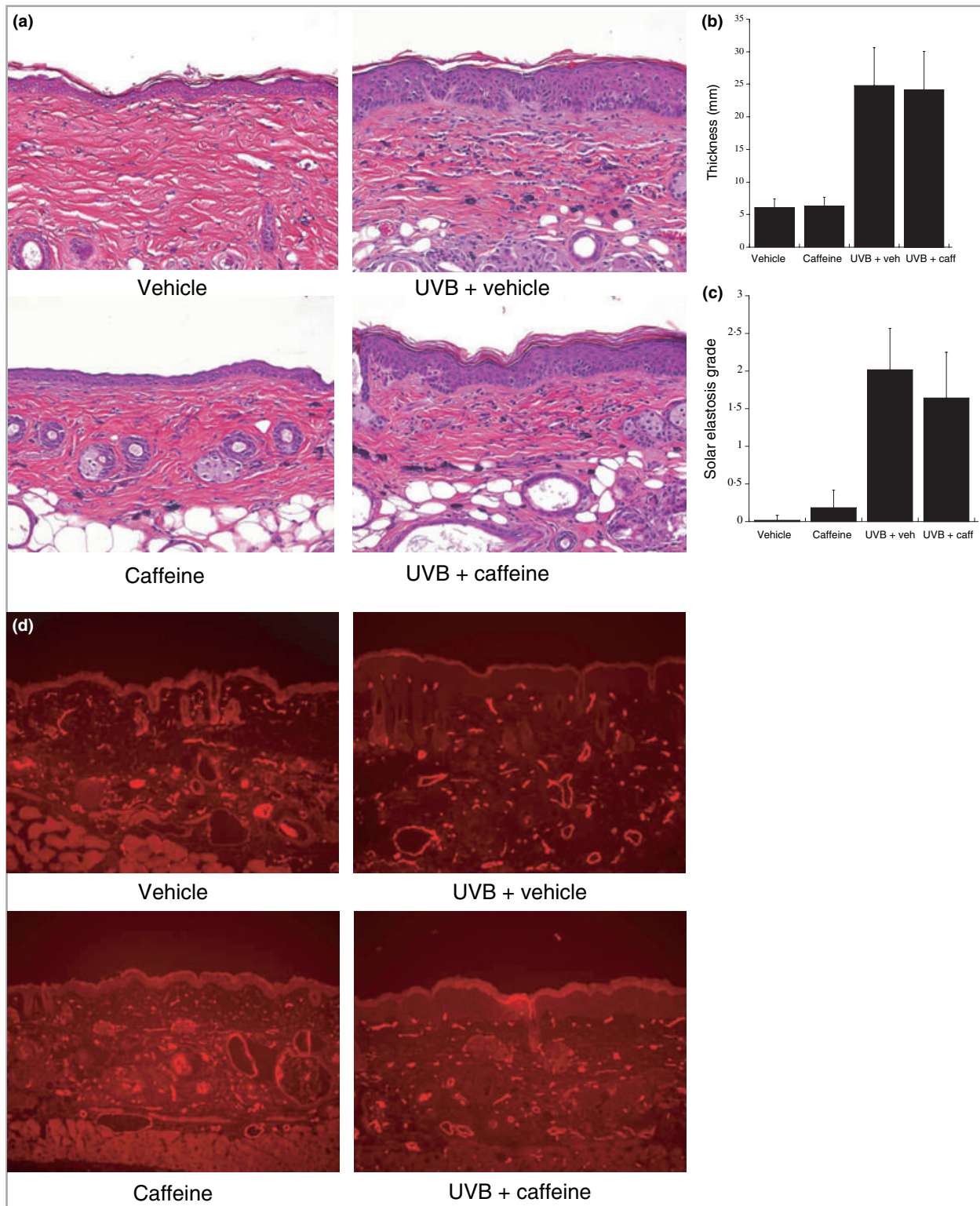


Fig 2. (a) Representative haematoxylin and eosin-stained sections of mouse back skin from each treatment group at the conclusion of the chronic ultraviolet (UV) experiment. (b) Mouse epidermal thickness. Each column indicates average thickness from the basal layer to the stratum corneum in the indicated treatment group. Twelve to 15 sections were evaluated for each treatment group. Error bar indicates standard deviation. 'caff' = caffeine; 'veh' = vehicle. (c) Solar elastosis. Each column indicates average grade of solar elastosis in each treatment group as described in Materials and methods. Twelve to 15 sections were evaluated for each treatment group. Error bar indicates standard deviation. (d) CD31 immunostaining for UV-induced angiogenesis.

frozen skin samples as described.²⁶ A marked increase in the number of blood vessels within 50 μm of the epidermal–dermal junction was noted in UV/vehicle and UV/caffeine treated mice relative to nonirradiated controls (Fig. 2d). However, UV/caffeine-treated mice demonstrated no significant difference compared with UV/vehicle-treated mice (Fig. 2d).

Effect of topical caffeine on the acute apoptotic response to ultraviolet B

In a short-term experiment (Fig. 3a) topical caffeine was applied to mouse back skin immediately after a single dose of UVB 45 mJ cm^{-2} . Skin was harvested 6 h later as pilot experiments revealed that this was the peak timepoint for UV-induced keratinocyte apoptosis under these conditions (data not shown). Haematoxylin and eosin staining of back skin in vehicle-treated and caffeine-treated mice showed no apoptotic keratinocytes (Fig. 3b). In contrast, apoptotic keratinocytes were observed in UV-treated mice and the addition of caffeine markedly increased the number of apoptotic/sunburn cells. These cells were further characterized as apoptotic cells by TUNEL staining (Fig. 3c) and caspase 3 cleavage (data not shown). As shown in Figure 3d there were 1.5 apoptotic keratinocytes per mm of UV/vehicle-treated skin compared with nearly four apoptotic keratinocytes per mm of UV/caffeine-treated skin ($P = 0.0095$).

Discussion

An important unmet need in dermatology is to understand and develop ways to ameliorate residual UV skin damage that later leads to photoageing and skin cancer development. Because topical caffeine applied after UVB can prevent the development of squamous cell carcinoma,¹⁷ we used the hairless mouse model to test whether topical caffeine applied following UVB exposure could prevent chronic UV damage in mouse skin. Consistent with its previously described effect on preventing UVB-induced skin cancer, topical caffeine significantly inhibited prior UVB exposure from inducing photodamage in this model. This effect was robust as judged by several examiners blinded as to the treatment. We examined a number of histological parameters that may relate to the decreased photodamage and found a trend toward decreased solar elastosis in caffeine-treated mice as well as a profound augmentation of keratinocyte apoptosis when caffeine was applied topically after UV.

A trivial explanation that we considered for this photoprotective effect was that caffeine, a known absorber in the UV spectrum,²⁷ had acted as a sunscreen. This is plausible because UVB/caffeine treatments were separated by as little as 48 h in our protocol and residual caffeine may have remained in the skin until the next UVB treatment. However, this possibility was effectively ruled out by the fact that UV-mediated induction of epidermal hyperplasia (Fig. 2a) as well as angiogenesis (Fig. 2d) were identical in UV/vehicle- and UV/caffeine-treated mice.

Although topical caffeine had a significant protective effect on visible UVB-induced skin changes and certain histological parameters, other histological studies were not markedly altered by topical caffeine. The precise histological alterations of photodamage in this model are not definitively known and we may not have assessed additional parameters that play a role in the observed findings.

However, we did observe that a significant histological finding—the extent of apoptosis observed after UVB—was markedly augmented by caffeine applied topically. Following a single dose of UVB 45 mJ cm^{-2} , topical caffeine application after UVB more than doubled the number of apoptotic keratinocytes at 6 h. This effect was robust as evaluated by three distinct measures of apoptosis: sunburn cell formation, caspase 3 cleavage and TUNEL staining. The stimulatory effect of topical caffeine on UVB-induced apoptosis in mouse skin suggests that DNA-damaged skin keratinocytes can be selectively killed by topical application of caffeine. An intriguing possibility is that deletion of this subset of damaged keratinocytes prevents the retention in the skin's cellular 'memory' of UV damage that later would cause both photodamage and skin cancer development.

One intriguing possible target of caffeine in skin after UV treatment is ATR, a protein kinase involved in sensing various stresses including UV DNA damage.^{18,19} Caffeine is an inhibitor of ATR and can 'override' the replication checkpoint function of ATR causing cells to undergo premature chromatin condensation and subsequent apoptosis.²⁰ Prior studies in our lab with cultured human osteosarcoma cells indicated that caffeine-induced inhibition of ATR caused premature chromatin condensation and cell death after UVB.²⁰ Previously, we also observed that cancer cells with p53 functional deficiency are selectively killed by ATR inhibition.^{20,28} As caffeine is a relatively weak inhibitor of ATR (high micromolar or low millimolar concentrations are required to inhibit ATR activity *in vitro*) it has not been an option to treat cancer patients systemically with caffeine due to cardiac arrhythmias and seizures that are induced at concentrations below those required to inhibit ATR. However, in the skin, caffeine applied topically can likely reach relatively high concentrations leading to biological effects, possibly through ATR inhibition.

Indeed, topical caffeine can selectively delete p53-mutant colonies of keratinocytes in intact skin. Lu *et al.*²⁴ reported that topical applications of caffeine immediately after UVB irradiation in p53(+/+) or p53(-/-) mice enhanced the UVB-induced increase in apoptotic sunburn cells by 127% and 563%, respectively, as would be expected of an agent that may inhibit photodamage by selectively deleting DNA-damaged cells. *In vitro* data suggest that the mechanism may involve inhibiting the ATR–Chk1 pathway but definitive data are not yet available.

The effects of topical caffeine on skin are also of interest as this agent is included in a number of skin care products marketed as lipolytics.^{21–23} Bertin *et al.*²¹ conducted a double-blind, randomized, placebo-controlled study with female volunteers in order to test an anticellulite product containing

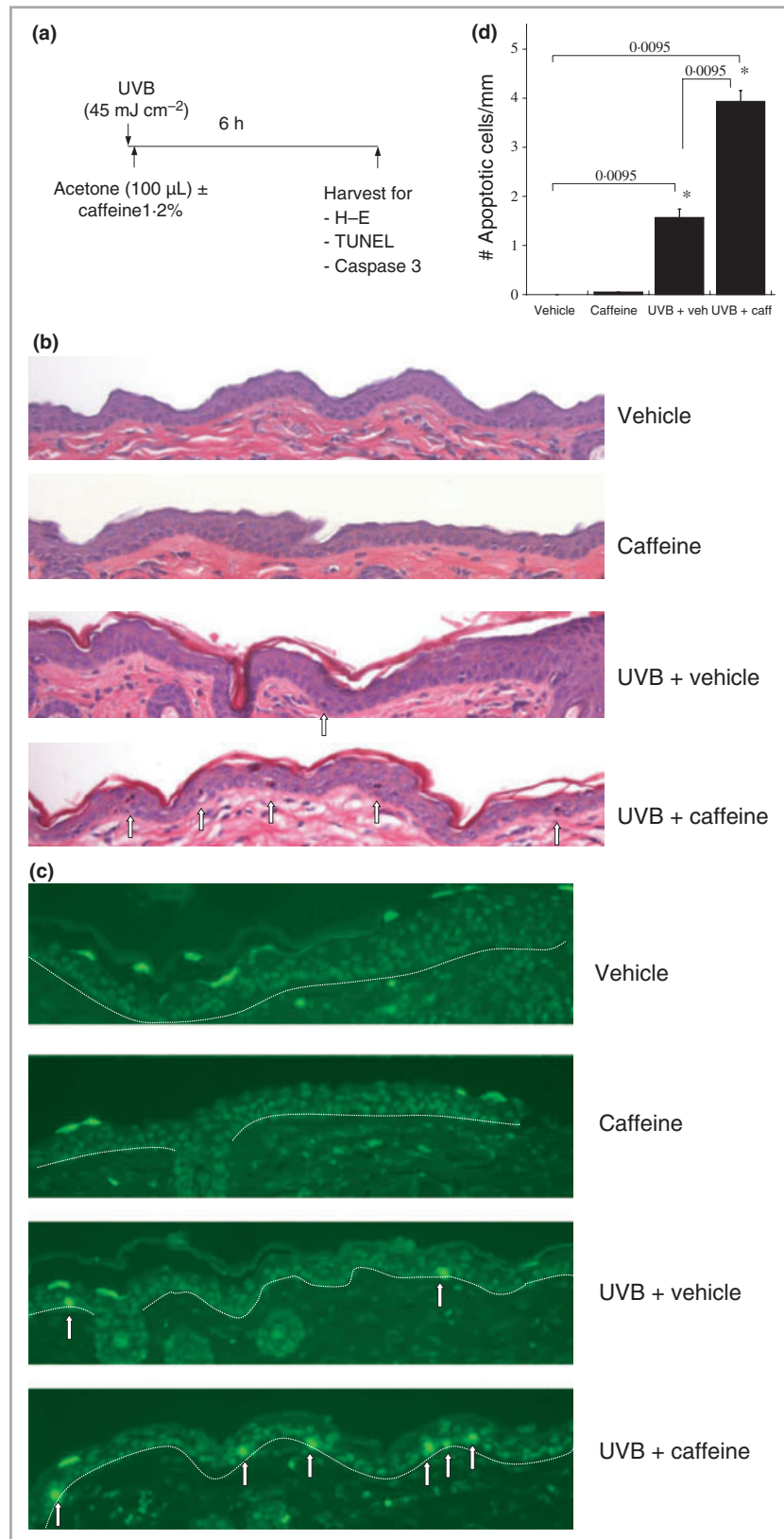


Fig 3. (a) Schematic of experiment to assess effect of topical caffeine on apoptosis following a single dose of 45 mJ cm⁻² ultraviolet (UV) (one minimal erythema dose in SKH-1 mice is ≈ 80 mJ cm⁻²). This design is identical to the initial phase of the chronic UV experiment (H-E, haematoxylin and eosin). (b) Apoptotic keratinocytes 'sunburn cells' are indicated by white arrows in these haematoxylin and eosin-stained sections. (c) Terminal deoxynucleotidyl transferase-mediated dUTP-biotin nick-end labelling (TUNEL) staining for apoptotic keratinocytes in the basal layer, as induced by UV and augmented by subsequent topical caffeine application. (d) Quantitation of apoptotic sunburn cells. Sunburn cells were counted on haematoxylin and eosin sections from five mice from each treatment group. Asterisk indicates statistically significant difference between treatment groups. P = 0.0095 via two-sided nonparametric Wilcoxon rank sum test.

retinol, caffeine and ruscogenine. Using this combination of active components, they observed a significantly greater lipolytic effect than with placebo. Sainio *et al.*²² reported that caf-

feine was the most common additive of cellulite creams, apparently representing an 'active' ingredient; however, little or no data has been published on the effects of topical appli-

cation of caffeine itself on skin. Increasingly, products including soaps ('Shower Shock') are marketed with caffeine added in the absence of data describing the effects of topical caffeine.

Because of the accepted safety profile of caffeine both topically and systemically, it is also possible to contemplate the addition of caffeine to sunscreen products. This would have several potential benefits relating to caffeine's ability to absorb as an additional sunscreen in the UV range and to its potential preventive effects on photodamage and photocarcinogenesis as described in mouse models. Based on these mouse models, detailed characterization of the effects of topical caffeine on human skin after UVB irradiation are thus indicated.

Acknowledgments

The authors thank Lynh Nguyen for expert technical assistance and Tim Heffernan, Xiaohui Bi, Pablo Penas, Irene Kochevar and Janice Brissette for helpful comments/suggestions. We thank Barry Starcher for desmosine/elastin quantitation studies. We also thank the Shiseido Corporation for support to the Cutaneous Biology Research Center.

References

- 1 Kligman AM. The treatment of photoaged human skin by topical tretinoin. *Drugs* 1989; **38**:1–8.
- 2 Leyden JJ, Grove GL, Grove MJ *et al.* Treatment of photodamaged facial skin with topical tretinoin. *J Am Acad Dermatol* 1989; **21**:638–44.
- 3 Gilchrist BA. A review of skin ageing and its medical therapy. *Br J Dermatol* 1996; **135**:867–75.
- 4 Hadshiew IM, Eller MS, Gilchrist BA. Skin aging and photoaging: the role of DNA damage and repair. *Am J Contact Dermat* 2000; **11**:19–25.
- 5 Brennan M, Bhatti H, Nerusu KC *et al.* Matrix metalloproteinase-1 is the major collagenolytic enzyme responsible for collagen damage in UV-irradiated human skin. *Photochem Photobiol* 2003; **78**:43–8.
- 6 Kripke ML. Ultraviolet radiation and immunology: something new under the sun—presidential address. *Cancer Res* 1994; **54**:6102–5.
- 7 Nishigori C. Cellular aspects of photocarcinogenesis. *Photochem Photobiol Sci* 2006; **5**:208–14.
- 8 Kligman LH, Akin FJ, Kligman AM. Prevention of ultraviolet damage to the dermis of hairless mice by sunscreens. *J Invest Dermatol* 1982; **78**:181–9.
- 9 Bissett DL, Hannon DP, Orr TV. An animal model of solar-aged skin: histological, physical, and visible changes in UV-irradiated hairless mouse skin. *Photochem Photobiol* 1987; **46**:367–78.
- 10 Sams WM Jr, Smith JG Jr. The histochemistry of chronically sun-damaged skin. An investigation of mucopolysaccharides and basophilia in actinically damaged skin using alcian blue, Mowry's, and Hicks–Matthaei stains, methylation, and saponification. *J Invest Dermatol* 1961; **37**:447–53.
- 11 Smith JG Jr, Davidson EA, Sams WM Jr *et al.* Alterations in human dermal connective tissue with age and chronic sun damage. *J Invest Dermatol* 1962; **39**:347–50.
- 12 Kligman AM. Early destructive effect of sunlight on human skin. *JAMA* 1969; **210**:2377–80.
- 13 Uitto J, Fazio MJ, Olsen DR. Molecular mechanisms of cutaneous aging. Age-associated connective tissue alterations in the dermis. *J Am Acad Dermatol* 1989; **21**:614–22.
- 14 Ibbotson SH, Moran MN, Nash JF *et al.* The effects of radicals compared with UVB as initiating species for the induction of chronic cutaneous photodamage. *J Invest Dermatol* 1999; **112**:933–8.
- 15 Fisher GJ, Datta SC, Talwar HS *et al.* Molecular basis of sun-induced premature skin ageing and retinoid antagonism. *Nature* 1996; **379**:335–9.
- 16 Kambayashi H, Yamashita M, Otake Y *et al.* Epidermal changes caused by chronic low-dose UV irradiation induce wrinkle formation in hairless mouse. *J Dermatol Sci* 2001; **27**(Suppl. 1):S19–25.
- 17 Lu YP, Lou YR, Xie JG *et al.* Topical applications of caffeine or (–)-epigallocatechin gallate (EGCG) inhibit carcinogenesis and selectively increase apoptosis in UVB-induced skin tumors in mice. *Proc Natl Acad Sci U S A* 2002; **99**:12455–60.
- 18 Zhou BB, Elledge SJ. The DNA damage response: putting checkpoints in perspective. *Nature* 2000; **408**:433–9.
- 19 Keith CT, Schreiber SL. PIK-related kinases: DNA repair, recombination, and cell cycle checkpoints. *Science* 1995; **270**:50–1.
- 20 Nghiem P, Park PK, Kim Y *et al.* ATR inhibition selectively sensitizes G1 checkpoint-deficient cells to lethal premature chromatin condensation. *Proc Natl Acad Sci U S A* 2001; **98**:9092–7.
- 21 Bertin C, Zunino H, Pittet JC *et al.* A double-blind evaluation of the activity of an anti-cellulite product containing retinol, caffeine, and ruscogenine by a combination of several non-invasive methods. *J Cosmet Sci* 2001; **52**:199–210.
- 22 Sainio EL, Rantanen T, Kanerva L. Ingredients and safety of cellulite creams. *Eur J Dermatol* 2000; **10**:596–603.
- 23 Tholon L, Neliat G, Chesne C *et al.* An *in vitro*, *ex vivo*, and *in vivo* demonstration of the lipolytic effect of slimming liposomes: an unexpected alpha(2)-adrenergic antagonism. *J Cosmet Sci* 2002; **53**:209–18.
- 24 Lu YP, Lou YR, Peng QY *et al.* Stimulatory effect of topical application of caffeine on UVB-induced apoptosis in the epidermis of p53 and Bax knockout mice. *Cancer Res* 2004; **64**:5020–7.
- 25 Starcher B, Conrad M. A role for neutrophil elastase in the progression of solar elastosis. *Connect Tissue Res* 1995; **31**:133–40.
- 26 Yano K, Oura H, Detmar M. Targeted overexpression of the angiogenesis inhibitor thrombospondin-1 in the epidermis of transgenic mice prevents ultraviolet-B-induced angiogenesis and cutaneous photo-damage. *J Invest Dermatol* 2002; **118**:800–5.
- 27 Kumbaraci NM, Nastuk WL. Action of caffeine in excitation–contraction coupling of frog skeletal muscle fibres. *J Physiol* 1982; **325**:195–211.
- 28 Nghiem P, Park PK, Kim YS *et al.* ATR is not required for p53 activation but synergizes with p53 in the replication checkpoint. *J Biol Chem* 2002; **277**:4428–34.